VERTICAL DIVISION
OF THE CORPUS CALLOSUM

Using Analyze

AnalyzeDirect

Table of Contents

Introduction

The Corpus Callosum

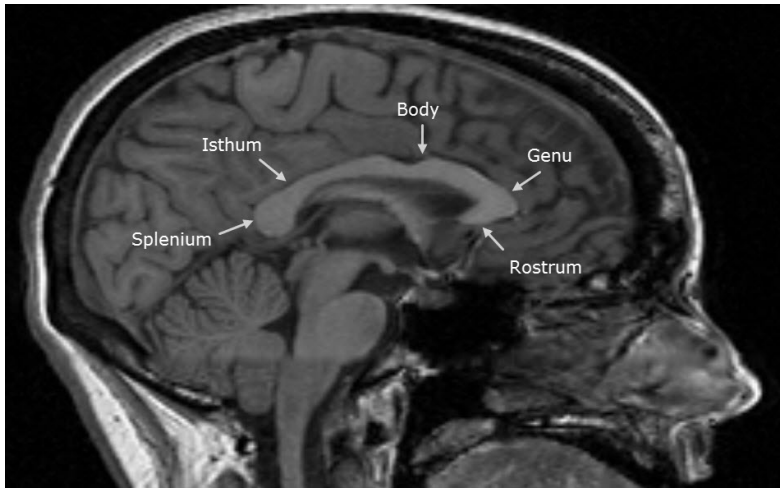

The corpus callosum connects the cerebral cortex of the left and right cerebral hemispheres, it is the largest fiber pathway in the brain and plays a vital role in interhemispheric communication.

The corpus callosum consists of 5 regions (posterior to anterior):

- Splenium
- Isthum
- Body
- Genu
- Rostrum

Given the importance of the corpus callosum it is naturally the focus of many active research studies. Examples of such studies include linking physical changes in the shape and structure of the corpus callosum with neurological impairments. Also of interest is establishing relationships between the different stages of a neurodegenerative diseases, such as Multiple Sclerosis, Schizophrenia or Alzheimer's, with physical alterations of the corpus callosum.

Vertical Division of the Corpus Callosum

Division of the corpus callosum on the mid-sagittal slice into its sub-structures is critically important to such research. Witelson *et al* proposes a strategy for division of the corpus callosum in "Hand and sex differences in the isthmus and Genu of the human corpus callosum: a postmortem morphological study". The methodology divides the corpus callosum into 7 parts, the body being split into the 3 sections — the posterior midbody, the anterior midbody and rostrum body.

This procedure has become a de facto standard for vertical division of the corpus callosum. This guide provides step-by-step instructions to dividing the corpus callosum as documented by Witelson *et al*.

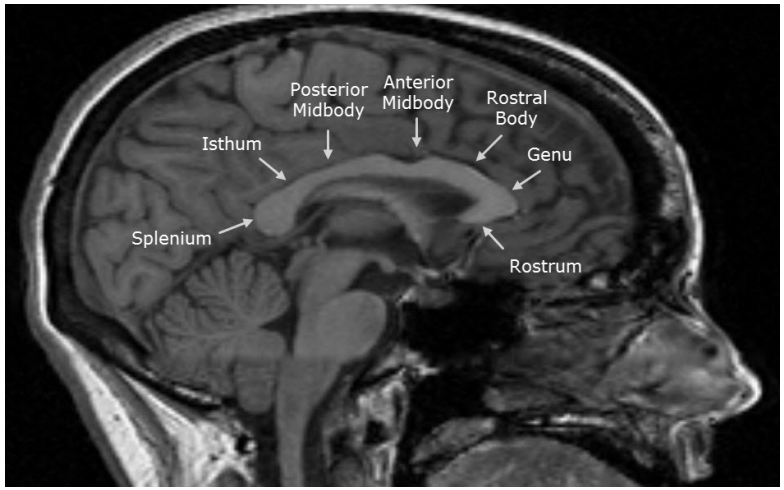

Procedure Overview

Vertical division of the corpus callosum uses the Region of Interest module's Auto Trace, Grid Divider and Placer tools to first define the gross anatomy of the corpus callosum and then to divide it into the appropriate 7 sub-structures:

Corpus Callosum Definition

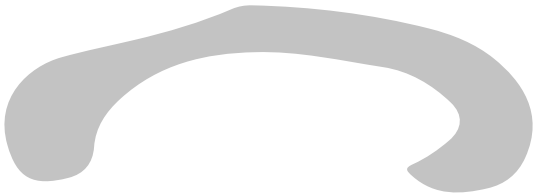

Corpus Callosum Division

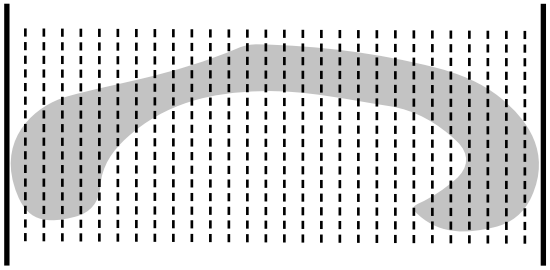

Sub-structure Definition, part 1

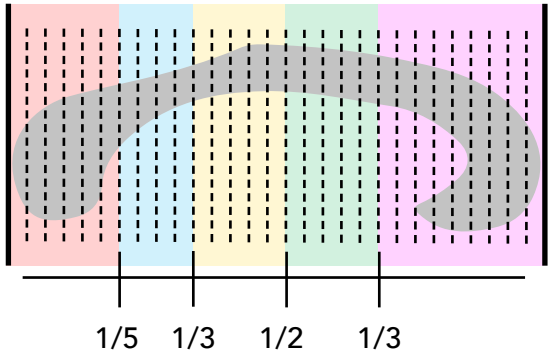

Sub-structure Definition, part 2

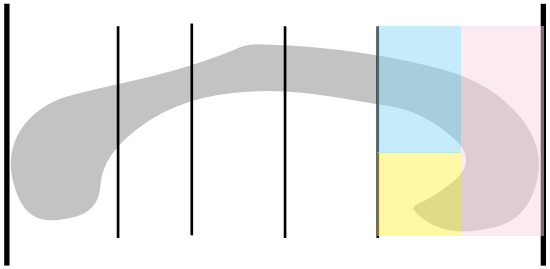

= Splenium
= Isthmus
= Posterior Midbody
= Anterior Midbody
= Rostral Body + Rostrum + Genu
= Rostral Body
= Genu
= Rostrum

Corpus Callosum Definition

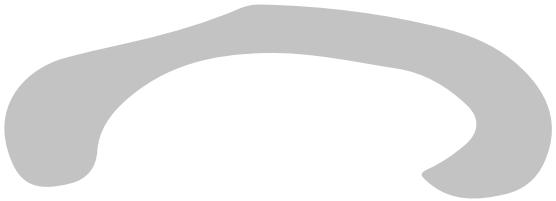

Select your data set and open **Measure > Region of Interest**.

Change to the sagittal orientation **Generate > Orientation**

Use the slice slider bar to navigate to a mid-sagittal slice.

 Select the **Auto Trace** tool.

Click in the corpus callosum to set a seed point. Using the double ended slider bar that appears below, adjust the minimum and maximum values until the corpus callosum is defined.

Click **Apply.**

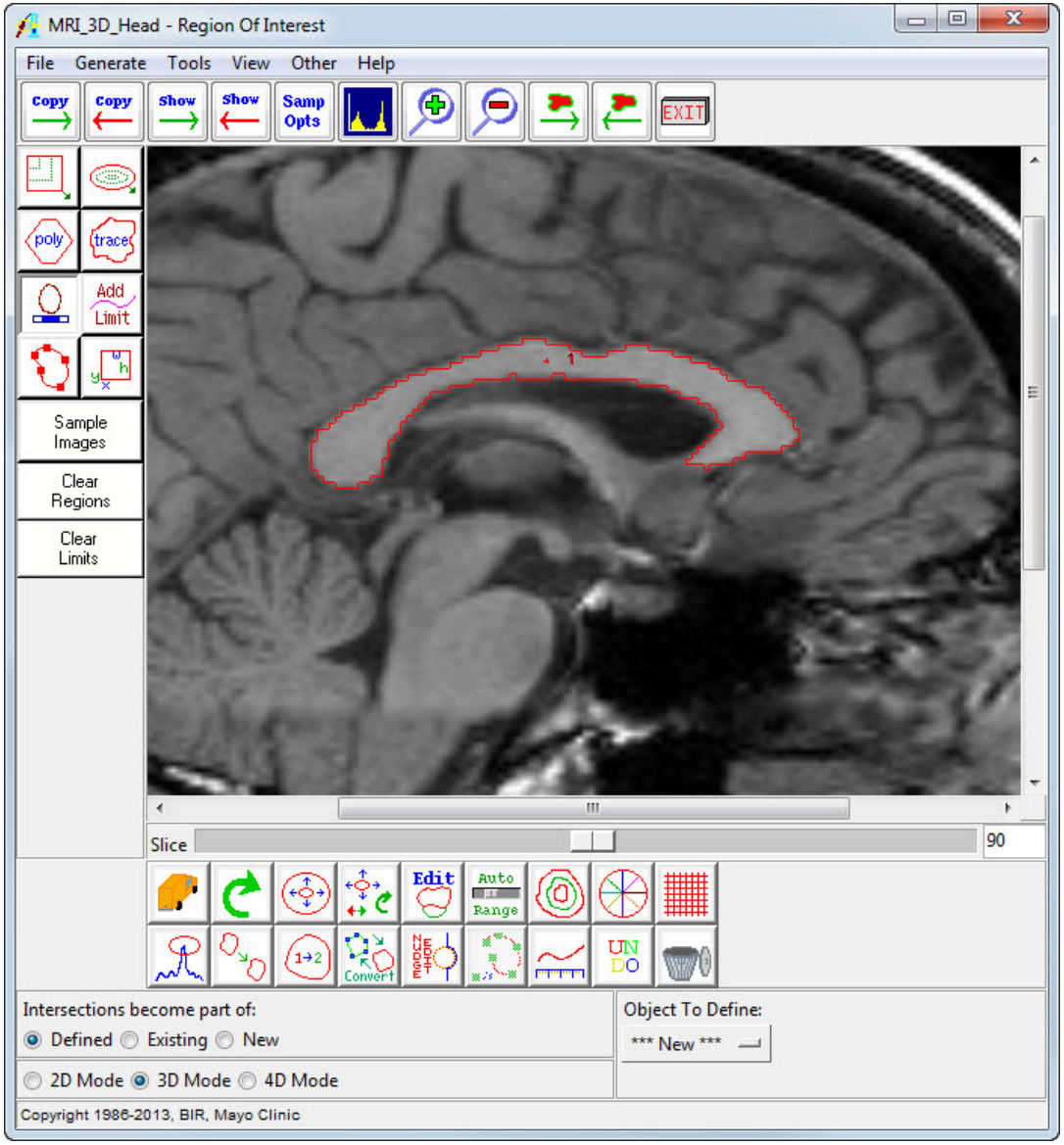

Corpus Callosum Division

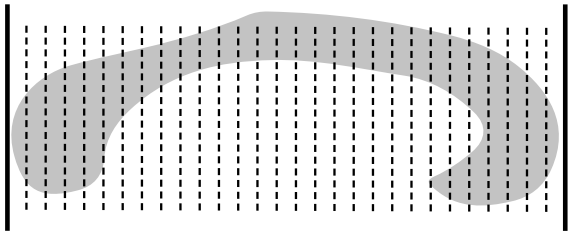

Witelson et al partition the corpus callosum on the mid-sagittal slice into sections based on fractions of its maximal size 1/5, 1/3, 1/2.

To replicate this with the ROI module, find the lowest common denominator for these regions, 30, and then split the corpus callosum into 30 equal regions. These regions can then be easily assigned to the appropriate sub-structure.

Select the **Grid Divider** Tool and set Rows to 1 and Columns to 30.

Then click inside the corpus callosum. The corpus callosum will be split into 30 equal sections.

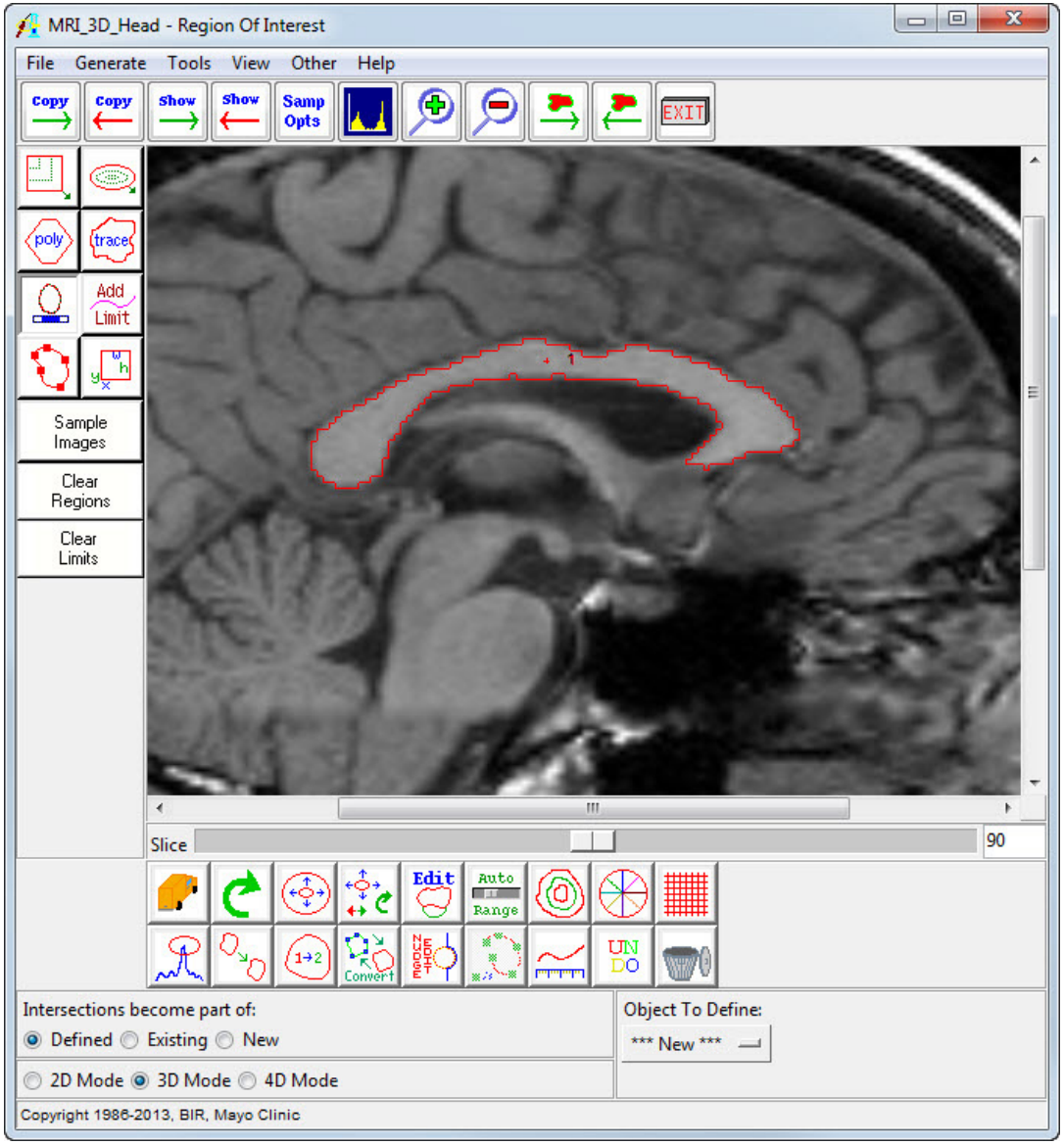

Sub-Structure Definition, part 1

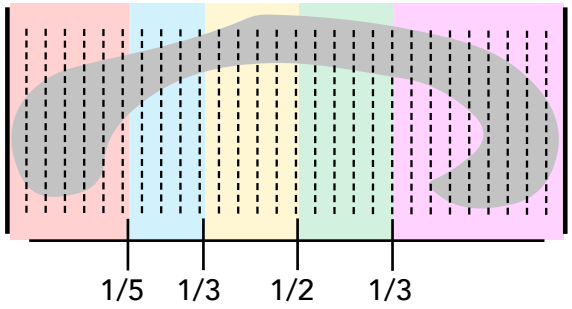

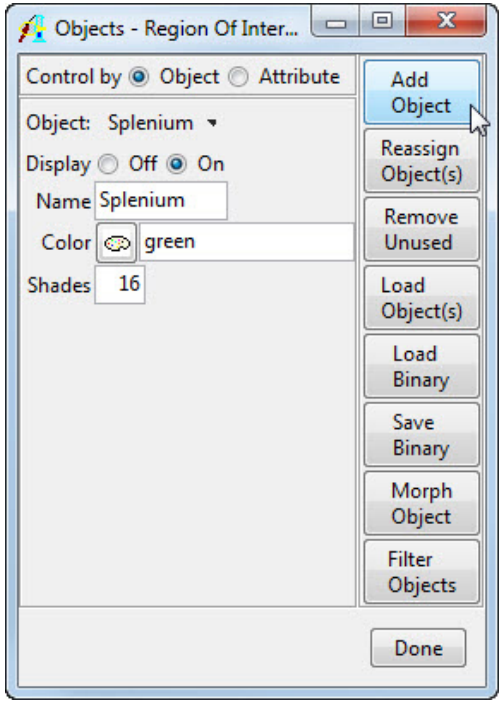

Next we will assign the 30 regions to their appropriate structure.

Open the Objects window (**View > Objects**)

Click the **Add Object** button seven times.

Rename the seven new objects to:

- Splenium
- Isthmus
- Post. Midbody
- Ant. Midbody
- Rostral Body
- Rostrum
- Genu

Click **Done** to dismiss the Objects window.

In the main ROI window, select the **Rename Region** tool. Set **Object To Define** to **Splenium**, then click on the six most posterior sections.

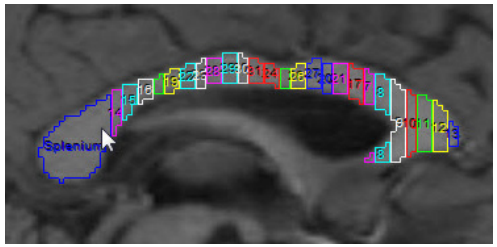

Change **Object To Define** to **Post Midbody** and define the Posterior Midbody object by clicking on the five sections anterior to the Isthmus object.

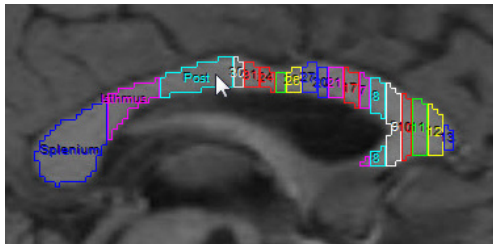

Set **Object To Define** to **Rostral Body** and click on the remaining sections in the corpus callosum.

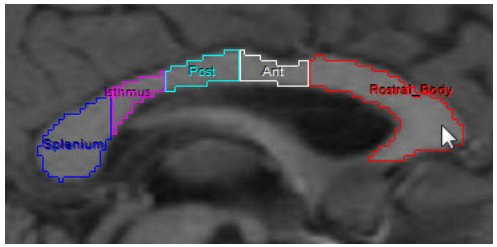

Change **Object To Define** to **Isthmus** and click on the four sections anterior to the Splenium object.

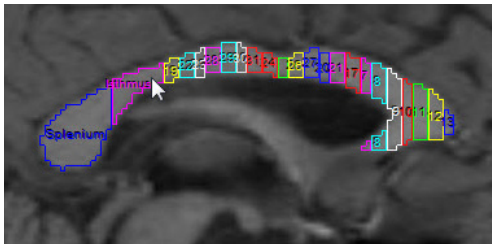

Change **Object To Define** to **Ant Midbody** and define the Anterior Midbody by clicking on the five sections anterior to the Posterior Midbody object.

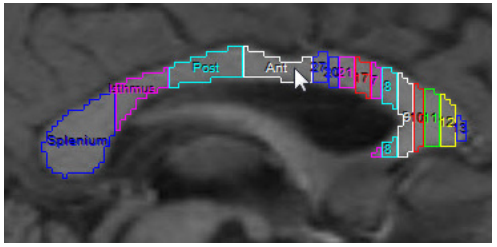

Sub-Structure Definition, part 2

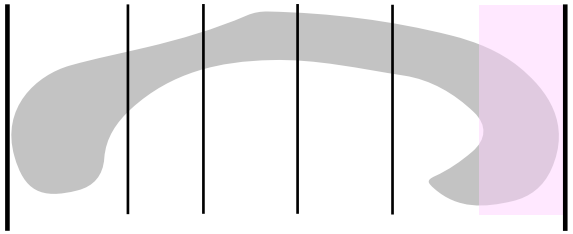

The next step in the process is to divide the rostal body object into the rostal body, genu and rostrum.

Set the **Object To Define** to ***New***.

Set the **Intersections become part of:** option to **New.**

Select the **Placer tool**, the Placer window will appear, adjust the X, Y position and the Width/Height of the Placer until it is positioned over the Genu (as shown in the image to the right).

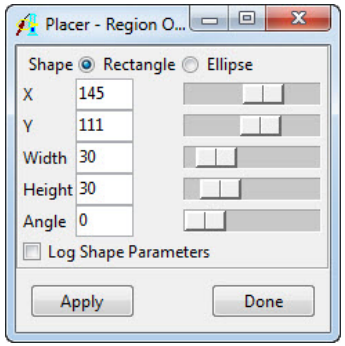

Click **Apply** in the Placer window, then click **Done** to close the window.

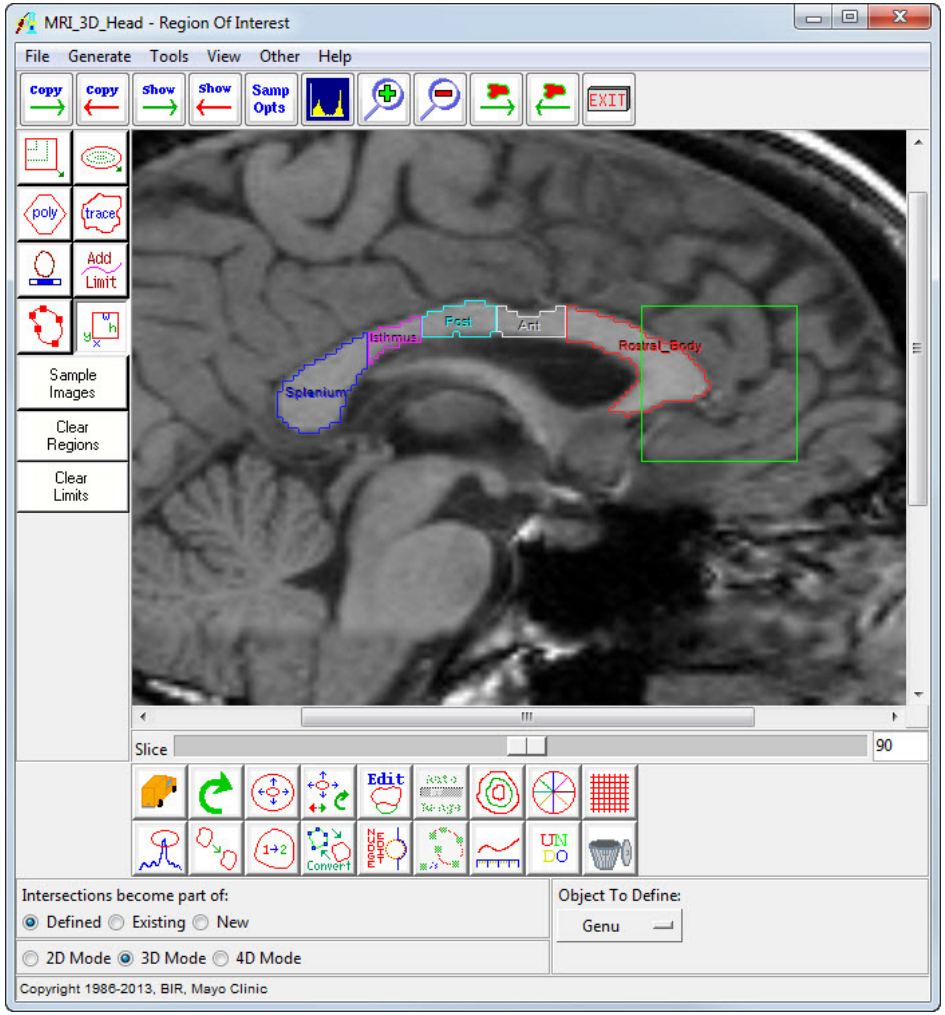

Genu and Rostrum Assignment

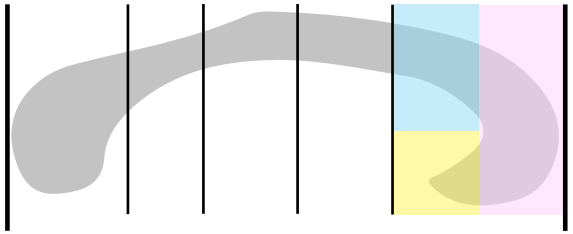

Set **Object To Define** to **Genu.** Select the **Rename Region** tool, and click on the Genu region.

To define the rostrum, set **Object To Define** to **Rostrum**, and click on the Rostrum region.

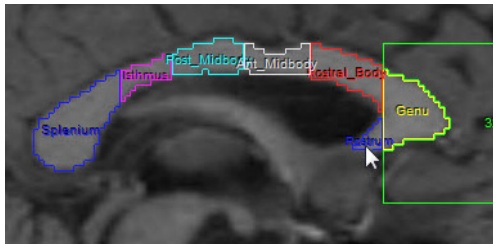

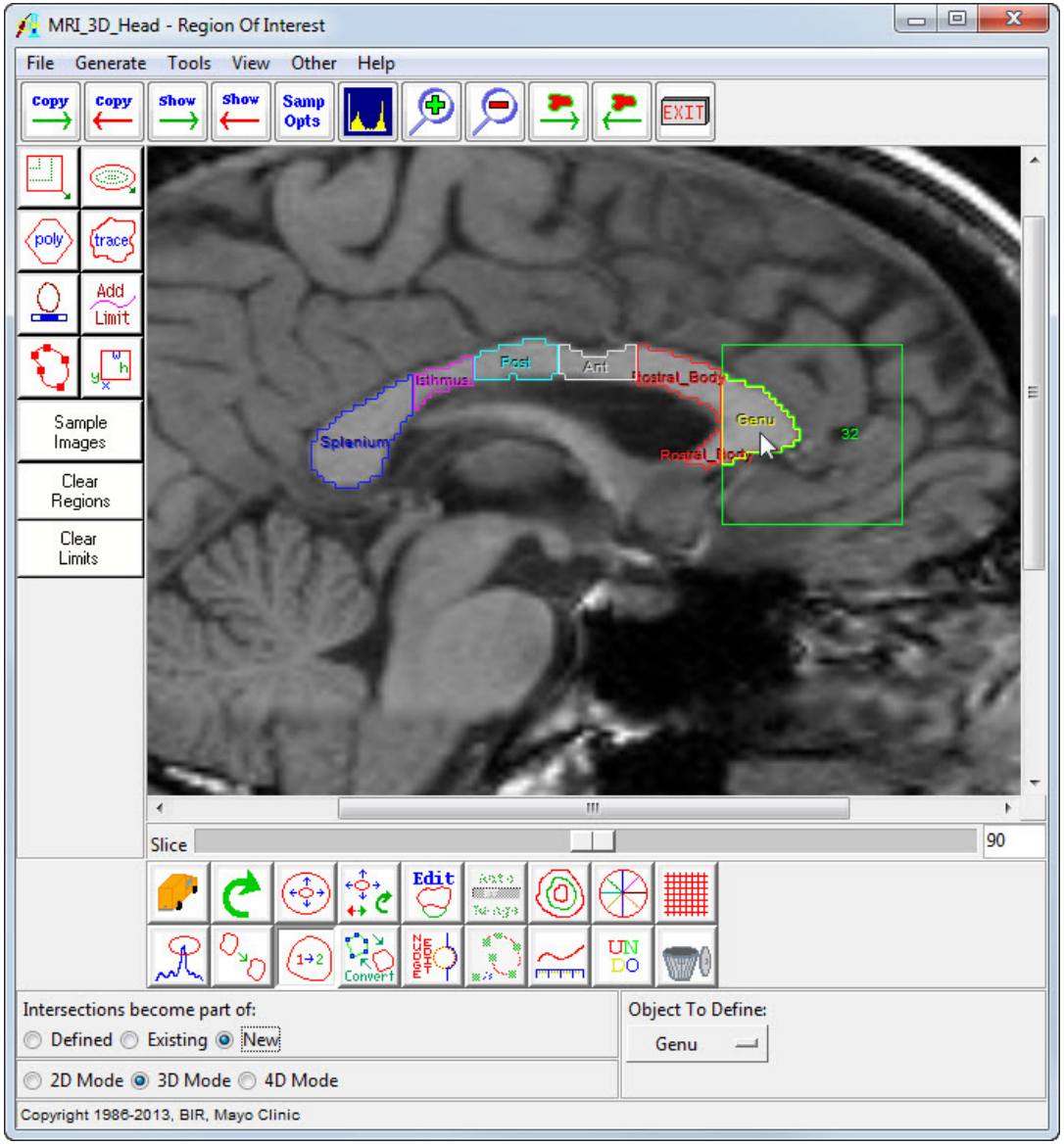

Object Map Clean Up and Saving

Select the Trash Can icon and click on the object surrounding the Genu to delete it.

To remove the remaining "empty" objects from the object map, select **View > Objects** and click Removed Unused button.

Save your work. Select **File > Save Object Map**.

To watch a video on how to measure each region, click here.

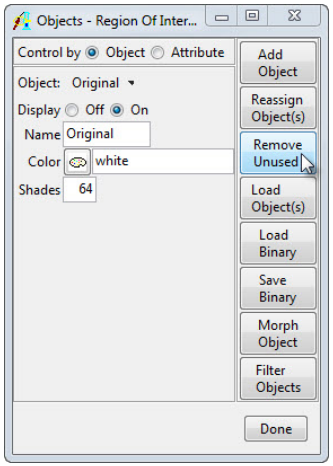

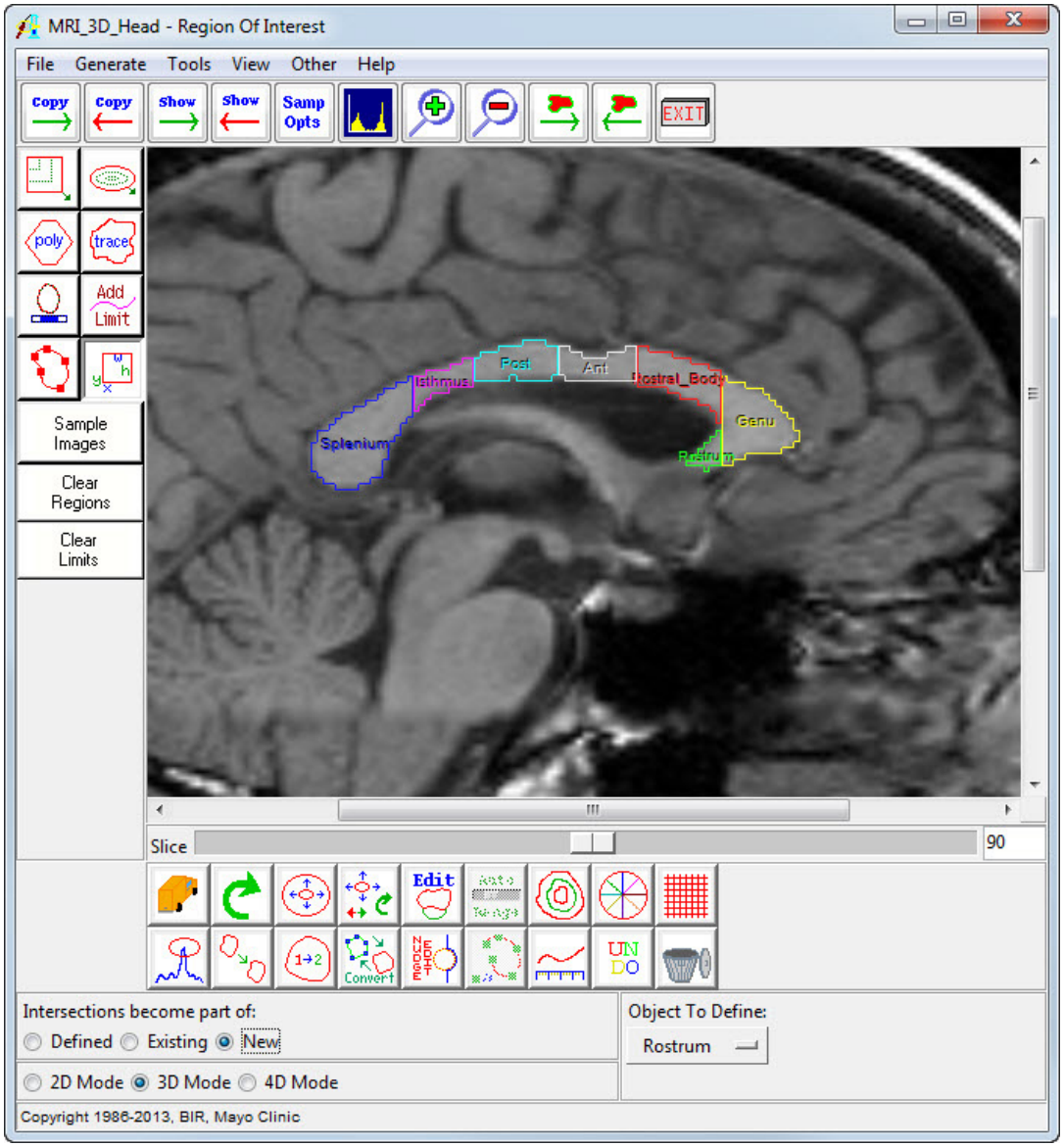

Learn more about Analyze

Visualization and Analysis Software for Medical Imaging

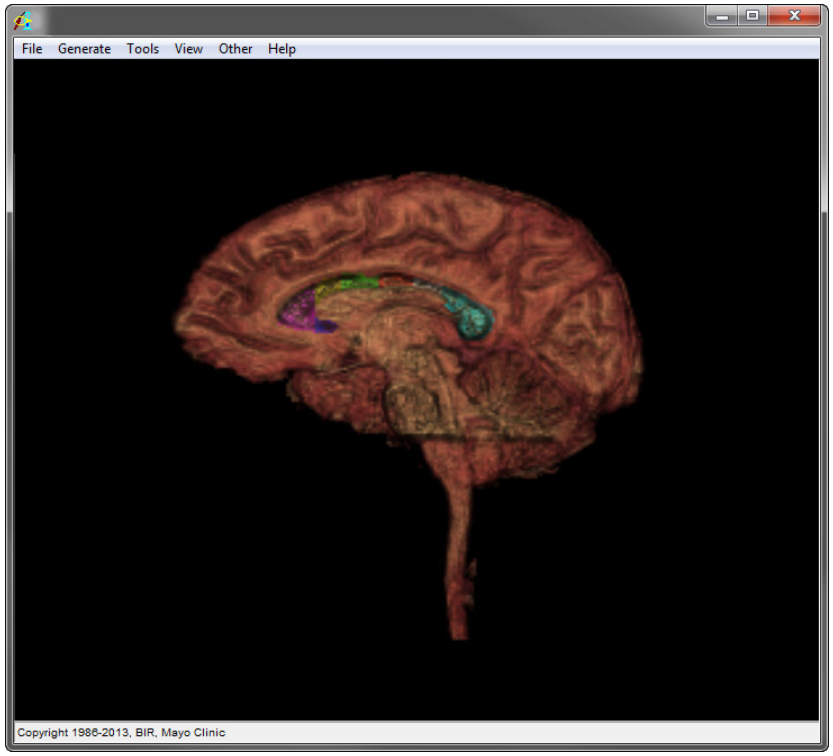

FREE TRIAL
Get Started Now